

Case Report

A Unique Case Report of Bilateral Rectus Sheath Block as a Sole Anaesthetic Technique for Umbilical Hernia Repair

Harshal Wagh, Milin Shah*

Department of Anaesthesia, Kokilaben Dhirubhai Ambani Hospital, Mumbai, India

Email address:

drhwdw2701@gmail.com (H. Wagh), drmilinshah7@gmail.com (M. Shah)

*Corresponding author

To cite this article:

Harshal Wagh, Milin Shah. A Unique Case Report of Bilateral Rectus Sheath Block as a Sole Anaesthetic Technique for Umbilical Hernia Repair. *International Journal of Anesthesia and Clinical Medicine*. Vol. 8, No. 2, 2020, pp. 65-67. doi: 10.11648/j.ijacm.20200802.17

Received: September 16, 2020; **Accepted:** September 28, 2020; **Published:** October 21, 2020

Abstract: *Background:* Rectus sheath block has been traditionally used to provide analgesia for anterior abdominal wall surgeries, as it spares the visceral pain component. It's been used efficiently for intraoperative, post-operative analgesia, providing stable hemodynamic. The emergence of ultrasound has potentially increased the rate of success, while avoiding complications like bleeding, peritoneal puncture, visceral injury. *Objective:* The author successfully used bilateral rectus sheath block for anesthesia of umbilical hernia repair about which very sparsely is described in literature. The use of ultrasound has increased the accuracy while decreasing the rate of complications. Also complications associated with general anesthesia and central neuraxial block can be avoided. *Method:* Obstructed umbilical hernia repair and ventral hernia repair were performed under sole ultrasound guided rectus sheath block. 5ml of 2% xylocard and 10ml of 0.75% ropivacaine was deposited on each side between rectus abdominis muscle and posterior rectus sheath. Both were high risk cases and some length of bowel handling was also involved. Yet the patients were comfortable with minimal supplemental analgesics and did not complain of any pain. *Conclusion:* Bilateral rectus sheath block can provide adequate anesthesia for abdominal hernia surgeries involving some bowel handling if supplemented by intravenous analgesics in high-risk cases. Thus avoiding general anesthesia and central neuraxial blockade.

Keywords: Peripheral Nerves Block, Anesthesia and Analgesia, Rectus Sheath Block, Hernia Repair

1. Introduction

Rectus sheath block was introduced by Schleich in 1899 [1]. By 2007 this advanced into ultrasound guided technique and placement of rectus sheath catheter [2].

Rectus sheath block is emerging as a valuable regional anesthesia technique. It can be used as an adjuvant or alternative to central neuraxial block and general anesthesia for surgeries of anterior abdominal wall, pediatric umbilical hernia, incisional hernia, laparoscopic surgeries and abdominal gynecological procedures and for analgesia [3-5].

A peripheral nerve block can avoid complications like spinal hematoma and hypotension associated with central neuraxial block and that of general anesthesia too. However chances of hematoma with deep peripheral nerve block should always be considered and American Society of Regional

Anesthesia guidelines for patients on anticoagulants should be followed [6].

First patient posted for emergency umbilical hernia surgery was on antiplatelet hence neuraxial block was ruled out. Due to multiple comorbidities, low ejection fraction and severe pulmonary artery hypertension, an ultrasound guided rectus sheath block was planned.

Second patient was posted for ventral hernia repair. For both patients general anesthesia and ICU backup was kept ready. Both the patients remained stable and comfortable throughout the procedure and in the post-operative period.

2. Case Report

2.1. Case One

A 67 year gentleman was admitted with the diagnosis of

obstructed umbilical hernia, posted for emergency repair. He was on regular medication for hypertension, type two diabetes mellitus, ischemic heart diseases with status post coronary artery bypass grafting 6 years ago, chronic kidney disease on multiple hemodialysis twice weekly since 2015 and last dialysis was done a day before the surgery and peripheral vascular disease.

His screening two D echo on admission reported an Ejection fraction 30% with Pulmonary artery systolic pressure of 80mmHg. His basic blood investigations were within normal limit except for serum potassium being 5.74 mEq/L.

2.2. Case Two

79 year lady was posted for suprapubic (ventral) hernia repair with Computed tomography Abdomen showing bowel loops in hernia. She was on regular medication for hypertension, diabetes mellitus, and ischemic heart diseases since 7 years, congestive cardiac failure and chronic obstructive pulmonary disease.

Her two D Echo showed an ejection fraction of 35% with inferior wall akinesia. Her blood investigations were normal.

2.3. Procedure

Proper counselling of the patients and their relatives was done and risk benefits of the block was explained. A written informed consent was taken.

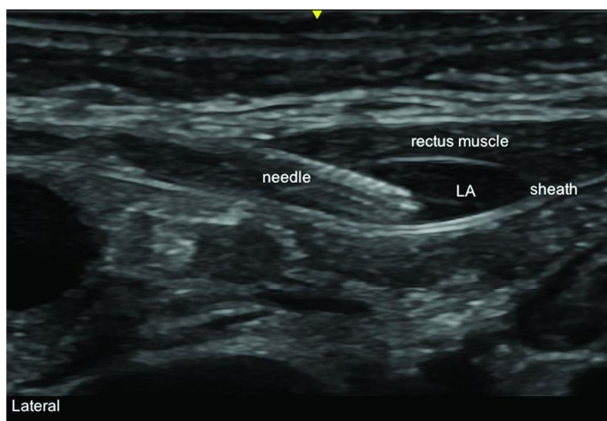


Figure 1. Ultrasound image of rectus sheath block in case one showing the needle and local anesthetic deposited.

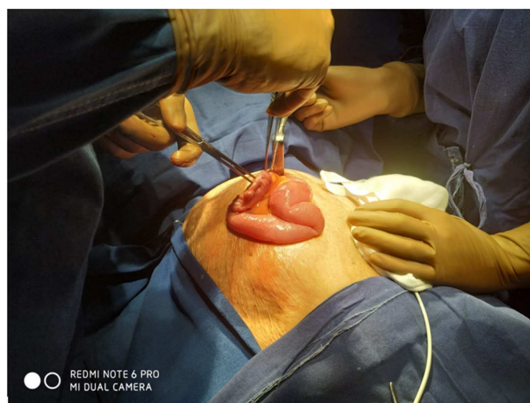

Figure 2. Bowel exteriorization in case two.

A 20G intra venous line was secured, standard monitors were attached. In supine position under strict asepsis, a real time ultrasound guided (HFL38x/13-6 MHz Linear Array Transducer; Sonosite M-Turbo™, Bothell, WA, USA) bilateral rectus sheath block was performed using a 22G (0.70 mm × 50 mm) Stimuplex® A insulated needle (B. Braun, Melsungen, Germany) via an in-plane approach. The site of needle insertion was just above the level of proposed incision. 5ml of 2% xylocard (100mgs) with 10ml of 0.75% ropivacaine (75mgs) was deposited on each side between rectus abdominis muscle and posterior rectus sheath [Figure 1].

Around one feet of small bowel was exteriorized in both the cases [Figure 2], without either patient complaining of any discomfort or pain, so resection and anastomosis or any bowel procedure, if needed could have been possible. Both cases were supplemented with intravenous inj. Fentanyl 50mcg and inj. Paracetamol 1gm intra operatively. They remained hemodynamically stable, comfortable and pain free throughout the surgery. At the end of the procedure the first patient was shifted to the Intensive Care Unit, his Visual Analogue Score was ≤ 2 and was subsequently shifted to wards after 2 days, while the second patient was shifted to Post anesthesia care unit and hemodynamic were monitored for 40 minutes which remained stable. Her Visual Analogue Score was ≤ 2 and was shifted to wards thereafter.

3. Discussion

The Rectus abdominis muscle is paired and is separated in the midline by linea alba. It is enclosed by the covering of rectus sheath which is deficit over the lower part of the muscle posteriorly [7]. The tendinous insertion between the rectus abdominis posteriorly and posterior rectus sheath do not extend entirely unlike with anterior rectus sheath and this helps in the spread of local anesthetics cephalo-caudally between rectus abdominis and posterior rectus sheath.

The use of ultrasound enables improved precision and accuracy, reduced anesthetic requirement, higher success rate and reduced complications.

The intercostal nerve (T7-T11), subcostal T12, and iliohypogastric (L1) and ilioinguinal (L1) are all the branches from anterior rami of spinal nerve that supplies the antero-lateral abdominal wall. They run in the neuro vascular plane between internal oblique and transverses abdominis muscle [7]. The anterior cutaneous branches of T7-T11 pierce the posterior rectus sheath and supply the overlying skin [10]. As a result rectus sheath block is useful for providing analgesia for anterior abdominal wall structures superficial to peritoneum and not to the visceral components [8-10].

Rectus sheath block is traditionally not indicated anesthetic technique for surgeries involving visceral structures. But as we observed in our case, some bowel handling and exteriorization was possible, with supplemental intravenous analgesics [10, 11].

There are a number of publications describing the value of rectus sheath block for analgesia or transverse abdominis block as a sole anesthetic technique. However very few

studies described bilateral rectus sheath used as a sole anesthetic technique [13-15]. Amongst them is an article published by Quek and phua in 2014 in Singapore medical journal for elective infra umbilical surgery [12].

The possibility of performing an obstructed umbilical or ventral hernia surgery and the fact the even a feet or two of intestine was exteriorized and handled in both the cases without much discomfort to the patient opens up an interesting debate of utilizing bilateral rectus sheath block as sole anesthetic technique.

4. Conclusion and Clinical Significance

In high risk cases, if somatic pain above the peritoneum is managed by adequate bilateral rectus sheath block than some bowel procedure or handling could be possible by supplemental intravenous analgesics. This will avoid unnecessary general anesthesia or neuraxial block and its related complications in high risk patients. However it would require a series of case study to actually recommend it as a sole anesthetic technique but can definitely be considered as an option in high risk cases with the surgical team been taken into confidence.

Even if not ideally indicated for visceral procedures, bilateral rectus sheath block should not be completely ruled out as sole anesthetic technique. Supplemented with intravenous analgesia and more case study, this block will gain more popularity in near future, especially for high risk cases.

Consent

The patient has given their informed consent for the case report to be published.

Competing Interest

The author (s) declare that they have no competing interests.

References

- [1] Schleich CL. *Schmerzlose Operationen*. Berlin: Springer; 1899: 240-1.
- [2] Sandeman DJ, Dilley AV. Ultrasound-guided rectus sheath block and catheter placement. *ANZ Journal of Surgery* 2008; 78: 621-3.
- [3] Azemati S, Khosravi MB. An assessment of the value of rectus sheath block for postlaparoscopic pain in gynecologic surgery. *J Minim Invasive Gynecol*. 2005; 12: 12-5.
- [4] Crosbie EJ, Massiah NS, Achiampong JY, Dolling S, Slade RJ. The surgical rectus sheath block for post-operative analgesia: a modern approach to an established technique. *Eur J Obstet Gynecol Reprod Biol*. 2012; 160: 196–200.
- [5] Gurnaney HG, Maxwell LG, Kraemer FW, et al. Prospective randomized observer-blinded study comparing the analgesic efficacy of ultrasound-guided rectus sheath block and local anaesthetic infiltration for umbilical hernia repair. *Br J Anaesth*. 2011; 107: 790–5.
- [6] Horlocker, Terese, T.; Vandermeulen, Erik; Kopp, Sandra, L.; Gogarten et al. *Regional Anesthesia in the Patient Receiving Antithrombotic or Thrombolytic Therapy: American Society of Regional Anesthesia and Pain Medicine Evidence-Based Guidelines (Fourth Edition)*. *Regional Anesthesia and Pain Medicine*. 2018; 44 (3): 2263-309.
- [7] J Yarwood and A Berrill. Nerve block of the anterior abdominal wall. *Continuing Education in Anaesthesia Critical Care & Pain*. 2010; 10 (6): 182-86.
- [8] Kelvin How Yow Quek, Daren Shing Kuan Phua. Bilateral rectus sheath block as the single anaesthetic technique for an open infraumbilical hernia repair. *Singapore Medical Journal*. 2014; 55 (3): 39-41.
- [9] Atkinson R, Rushman G, Lee J. A synopsis of anaesthesia. 10th ed. Bristol: Wright; 1987: 637-40.
- [10] Muir J, Ferguson S. The rectus sheath block - well worth remembering. *Anaesthesia*. 1996; 51: 893–4.
- [11] Phua DS, Phoo JW, Koay CK. The ultrasound-guided rectus sheath block as an anaesthetic in adult paraumbilical hernia repair. *Anaesth Intensive Care*. 2009; 37: 499–500.
- [12] Quek KH, Phua DS. Bilateral rectus sheath blocks as the single anaesthetic technique for an open infraumbilical hernia repair. *Singapore Med J*. 2014; 55 (3): e39-e41. doi: 10.11622/smedj.2014042.
- [13] Hariharan U, Baduni N, Singh BP. Bilateral rectus sheath block for single-incision laparoscopic tubal ligation in a cardiac patient. *J Anaesthesiol Clin Pharmacol*. 2016; 32 (3): 414-415. doi: 10.4103/0970-9185.173396.
- [14] López-Herrera-Rodríguez D, Guerrero-Domínguez R, Acosta-Martínez J, Sánchez-Carrillo F. Bloqueo de la vaina de los rectos ecoguiado para reparación de hernia umbilical en un paciente con síndrome de Wolff-Parkinson-White: reporte de un caso. *Rev Colomb Anestesiol*. 2015; 43: 343–345.
- [15] Manassero A, Bossolasco M, Meineri M, Ugues S, Liarou C, Bertolaccini L. Spread patterns and effectiveness for surgery after ultrasound-guided rectus sheath block in adult day-case patients scheduled for umbilical hernia repair. *J Anaesthesiol Clin Pharmacol* [serial online] 2015 [cited 2020 Sep 27]; 31: 349-53.