

Peri-Operative Management of a Von Recklinghausen's Disease Royal Tumor: About a Case

Mbaye Diaw^{1,*}, Papa Alassane Leye^{2,3,*}, Alioune Badara Thiam⁴, Abdou Kane Diop³,
El Hadj Ndiassé Diop², Ndeye Aissatou Bagayogo², Sagar Diop⁴,
Mouhamadou Moustapha Ndongo⁴, Papa Ibrahima Ndiaye^{2,3}, Elisabeth Diouf^{2,3}

¹Anesthesia and Critical Care Medicine, Cheikh Anta Diop University (UCAD), Dakar, Senegal

²Faculty of Medicine, Pharmacy and Odonto-Stomatology, Cheikh Anta Diop University (UCAD), Dakar, Senegal

³Department of Anesthesia and Critical Care Medicine, Aristide Le Dantec University Hospital, Dakar, Senegal

⁴Department of Neurosurgery, Fann University National Hospital, Dakar, Senegal

Email address:

diawfara86@gmail.com (M. Diaw), palassaneleye@yahoo.fr (P. A. Leye)

*Corresponding author

To cite this article:

Mbaye Diaw, Papa Alassane Leye, Alioune Badara Thiam, Abdou Kane Diop, El Hadj Ndiassé Diop, Ndeye Aissatou Bagayogo, Sagar Diop, Mouhamadou Moustapha Ndongo, Papa Ibrahima Ndiaye, Elisabeth Diouf. Peri-Operative Management of a Von Recklinghausen's Disease Royal Tumor: About a Case. *International Journal of Anesthesia and Clinical Medicine*. Vol. 10, No. 1, 2022, pp. 38-43.

doi: 10.11648/j.ijacm.20221001.17

Received: May 16, 2022; Accepted: June 14, 2022; Published: June 27, 2022

Abstract: The royal tumor is a very hemorrhagic tumor reflecting the preponderant and monstrous development of a plexiform neurofibroma or a deep tumor of a nerve trunk. We report the case of a 29-year-old patient with a large and painful tumor attached to the lumbosacral region by an implantation base 40cm wide, avoiding dorsal decubitus and associated with symptoms of slow dorsal spinal cord compression and diffuse cutaneous neurofibromas localized on the face, neck and thorax. MRI showed a large soft tissue tumor with intraspinal invasion in D8. Histology of the tumor confirmed the diagnosis of neurofibromatosis at the stage of cancerization with a profile in favor of a leiomyosarcoma with a myxoid aspect. We present through this case the possibility of the preponderant and monstrous development of a neurofibroma of Von Recklinghausen, his cancerization and the challenge of the anesthetic management.

Keywords: Neurofibroma, Von Recklinghausen, Anesthesia, Dakar

1. Introduction

Neurofibromatosis was first described in 1882 by Von Recklinghausen as a genetic neuroectodermal abnormality with systemic and progressive involvement, which mainly affects the skin, nervous system, bones, eyes and possibly other organs [1]. It is an autosomal dominant disorder whose diagnosis remains clinical with defined criteria. Cutaneous manifestations come to the fore with café-au-lait spots, ephelides and cutaneous neurofibromas [2].

The royal tumor reflected the preponderant and monstrous development of a plexiform neurofibroma or a deep tumor of a nerve trunk [3]. It is a tumor that is most often benign but has a risk of malignant degeneration [4].

Their perioperative management poses several problems: the

risk of difficult intubation planned with the supine position which is impossible, ventilation in prone position throughout the duration of the surgery which is long, the risk of haemorrhage, hemodynamic and massive transfusion incapacity.

2. Observation

He is a 29-year-old patient, carrier of Von Recklinghausen neurofibromatosis and orthopedic malformations of the legs, received for slow dorsal spinal cord compression evolving for 1 month.

The onset of symptoms dates back to childhood.

For 3 years, he has had a royal dorsal tumor with an increase in size and aggravation of pain in the previous 3 months and an occurrence of neurological disorders such as

gait disorders. There was no family history of neurofibroma.

In his surgical history, we note an intervention at the age of 1 year for malformations of the legs in 1993.

The preoperative evaluation found a preserved general condition, colored mucous membranes. The constants were with blood pressure at 13/8 cmHg and heart rate at 110 beats per minute.

The physical examination revealed a large dorsal royal tumor about 35-40 cm in diameter, preventing dorsal decubitus, painful without inflammatory or vascular character, diffuse cutaneous neurofibromas localized on the face, neck and thorax. There was flaccid paraplegia with D12 hyperesthesia associated with sphincter disorders such as urinary incontinence.

There was also an arched deformity of the legs with surgical scars. The diagnosis of neurofibromatosis type 1 is made in the presence of the association of all these signs. It is probably a sporadic form of the disease, the interrogation not having found any family history.

There was no predictive criterion for difficult intubation apart from impossible supine position.

The patient was under analgesic and anticoagulation treatment with enoxaparine at a preventive dose.

Biology was normal with hemoglobin at 13 g/dl, platelets at 356,000/mm³, PT at 87%, creatinine at 8.6 mg/l.

MRI showed a large soft tissue tumor with intraspinal invasion in D8.

General anesthesia was performed after pre-oxygenation with 6l nasal prongs for 5 minutes in a seated position then with a face mask and pre-filling with 500 ml of saline Rapid sequence induction was performed with ketamine 100 mg MDZ 4 mg propofol 100 mg and suxamethonium 80mg.

Then as soon as narcosis was obtained, the patient was placed in the left lateral position with an assistant supporting the head.

Orotracheal intubation with a 7.5 reinforced tube fitted with a stylet was performed after 2 attempts at the video laryngoscope.

Additional anesthesia with fentanyl 250 gamma and vecuronium 8 mg was performed.

The patient was installed in ventral decubitus with blocks under the thorax at shoulder height and at the level of the pelvis with verification of the freedom of the neck and abdomen.

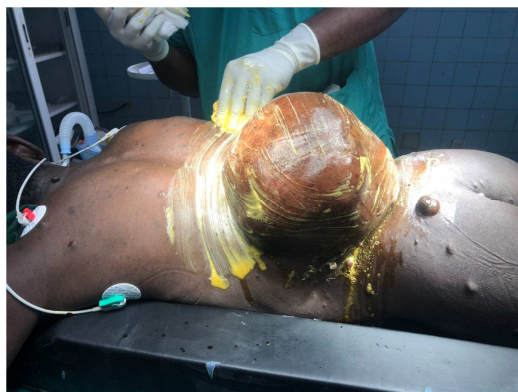

Figure 1. The royal tumor on patient intubated in prone position.

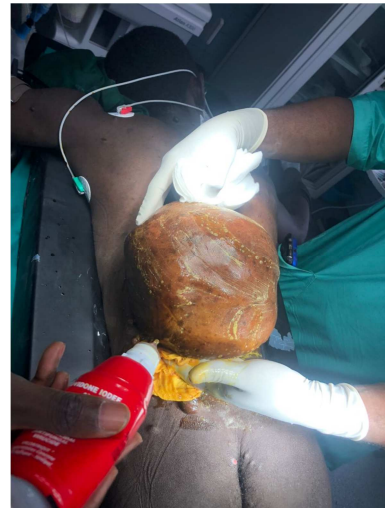


Figure 2. The royal tumor.

Ventilation was done in controlled pressure with the following ventilatory parameters: Inspiratory pressure at 22 giving a tidal volume at 600, a respiratory rate at 14 and a positive expiratory pressure PEEP at 4.

Maintenance of anesthesia with isoflurane between 1-1.5%, fentanyl 3 reinjections of 100 gamma and vecuronium 3 reinjections of 2 mg, ketamine 3 reinjections of 100 mg.

Prophylactic antibiotics were given with ceftriaxone 2g then reinjection of 1g, prevention of bleeding with tranexamic acid 1g then 500 mg at the end of the operation and an injection of solumedrol 120 mg.

Blood loss was estimated at 2000 ml of blood.

The patient benefited from a vascular filling with 4 liters of saline solution, 1.5 liters of gelofusine, a transfusion of 4 PFCs and 4 red cells isogroup isoRH AA+; he remained hemodynamically stable throughout the procedure.

The incision was of the “orange wedge” type of the tumor, then dissection was carried out according to a cleavable plane and the tumor was clearly excised. The patient also underwent a D8, D9, D10 and D11 laminectomy.

On exploration, there was also infiltration of the soft tissues and lysis of the vertebral laminae and spinous processes.

Before closing the dorsal incision, the patient received an intrathecal injection of 200 gamma morphine.

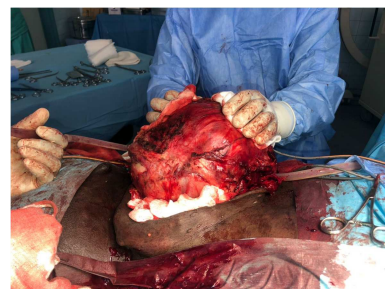

Figure 3. The royal tumor, after incision.

At the end of the intervention, the patient was returned to the supine position and then transferred to intensive care

intubated and ventilated. The surgery lasted 7 hours.

The postoperative biological assessment noted: mild anemia at 9.9 g/dl, platelet count at 153,000/mm³, WBC at 13,500/mm³, PT at 66%, serum creatinine at 6.1 mg/l and Natremia at 135 mmol/l, potassium at 3.4 mmol/l.

Extubation was done at H1 postoperative.

In terms of analgesia, our patient benefited postoperatively from a protocol that included;

- Paracetamol 1g 4 times a day combined with tramadol 400mg + levosulpiride 100mg with an electric syringe pump and profenid 100mg 3 times a day.

This made it possible to have VAS scores below 3.

The postoperative course was simple. The patient was discharged from the hospital on D10.

The anatomopathological-pathological examination of the surgical specimen confirmed the diagnosis of neurofibromatosis at the stage of cancerization with a profile in favor of a leiomyosarcoma of myxoid aspect.

3. Comments

Neurofibromatosis type 1 or Von Recklinghausen's disease is the most common phacomatosis [5]. Neurofibromas are usually benign tumors of the peripheral nerves. They are multiple, with diffuse distribution, characterized by infiltration of the skin or soft tissues [6] and present a rare risk of sarcomatous degeneration. They are generally slow-growing tumours, however the evolution of their growth is unpredictable.

The localization of the royal tumor is variable, it can also develop in the lower limbs as is the case in a Malagasy patient who presented with a bulky royal tumor hanging from the thigh [7].

Our patient received general anesthesia with a rapid sequence induction due to the planned difficult intubation with the supine position which was impossible. This is how videolaryngoscopy was prepared and used to reduce the risk of intubation failure and to reduce delays and the number of attempts.

The hypnotic used was propofol for its rapidity of action. Rapid sequence induction was performed with a short-acting curare in accordance with the recommendations, in this case suxamethonium [8]. Indeed, this depolarizing muscle relaxant has a very short onset of action (less than 1 minute) and a short duration of action (10 minutes) and offers excellent intubation conditions [9].

In anesthesia, intubation is very often done with a patient in the supine position, intubation in the lateral position being an uncommon procedure. However, in some cases, it is the clinical condition of the patient and his pathology that require it. These may be bulky tumors that prevent dorsal decubitus, as is the case in our patient, or certain dyspneic pathologies in strict dorsal decubitus or massive upper gastrointestinal bleeding.

Lateral decubitus intubation can be difficult to achieve due to poor visibility of glottic and supraglottic structures during direct laryngoscopy [10].

The use of new videolaryngoscopy equipment (Videolaryngoscopes, Truview®, C-MAC®, Airwayscope®, Airtraq®) has considerably facilitated this procedure by improving laryngeal visibility compared to conventional direct laryngoscopy [11].

Indeed, the literature has shown that intubation in the lateral position becomes easier with the use of videolaryngoscopy, minimizing the percentage of failure and complications (dysphonia, postoperative tracheal gene) but with a time of realization almost similar (10 seconds) compared to the supine position and an insignificant number of attempts [12].

Cormack Lehane scores are better with the use of videolaryngoscopy compared to direct laryngoscopy [12] with a lower rate of oral mucosal lesions and external tracheal maneuver (Sellick maneuver).

Videolaryngoscopy is better than direct laryngoscopy for planned or unplanned difficult intubation [11].

The second problem posed by the intervention is the prone position. The imperatives of the installation are to reduce the venous pressure of the epidural space and to open the interlaminar spaces by placing the lumbar spine in kyphosis. The absence of abdominal compression is imperative to reduce the pressure in the epidural venous plexuses at the origin of the bleeding [13, 14].

The prone position exposes to the following risks: [13-15].

1. Traumatic lesions and compressions of the eyeballs (corneal lesions and optic neuritis) ischemic.
2. Peripheral nerve damage.
3. Risk of hypoventilation by abdominal compression (especially in obese patients) as well as a risk of kinking of the intubation tube and/or extubations and selective intubations.
4. Decreased venous return by various mechanisms: compression of the diaphragm, abdominal compression of the inferior vena cava and the femoral vein and consequently a decrease in cardiac output.
5. Cutaneo-mucous and muscular postural lesions: the maximum pressures are measured at the level of the knees and the iliac crests in ventral decubitus.
6. Hyperlordosis increases the risk of shearing by forward or downward positions.
7. The auricular cartilages can be injured in the event of kinking during the positioning of the head in rotation.
8. Painful bilateral edema of the submandibular salivary glands when the head is rotated.
9. Risk of parotid lesions, macroglossia and oropharyngeal edema.
10. A duration of surgery greater than 4 hours triples the risk of injury.

In our patient, who was in a flat prone position with a slightly broken table, various measures were taken to prevent these risks associated with prone position:

1. Effective and gentle eyelid occlusion with the use of a headrest and iterative verification of ocular compression.
2. Moderate rotation of the head which rested on a padded crown with a field for facial support.

3. Maintaining the spine in a neutral position.
4. The use of a reinforced intubation tube with a double fixation.
5. Regular auscultation and capnogram monitoring.
6. Maintenance of optimal hemodynamics and prevention of hypothermia (warmer) to prevent skin and muscle damage.
7. The use of a single padded rectangular block, the two widths of which are placed at the level of the shoulders (sides above the nipples) and the pelvis (iliac crests) to avoid any cervical and abdominal compression and to promote abdominal expansion and enlargement of the rib cage and therefore the ventilation.
8. The placement of padded fields under the knees and ankles.
9. Verification of the freedom of the external genitalia.
10. The use of adjustable padded armrests, supporting the arms with elbows bent at 90 degrees, hands in pronation, padded drapes under the elbows and under the shoulders to avoid any stretching of the brachial plexus.

Spinal tumor surgery is a double haemorrhagic surgery.

According to the HAS checklist, perioperative bleeding is significant when it exceeds 500 ml or 7 ml/kg in paediatrics. In the literature, the volume of blood loss in major spinal surgery varies between 1000 ml and 5000 ml [16].

Anemia is an independent risk factor for morbidity and mortality in perioperative patients [17].

In our patient, blood loss was estimated at 2000 ml.

Various measures are taken to prevent perioperative bleeding:

1. Detection of a haemostasis anomaly with a risk of haemorrhage preoperatively. Our patient had a correct hemostasis assessment.
2. Correction of hemostasis disorders with hemorrhagic risk. The platelet transfusion threshold in surgery is $50,000/\text{mm}^3$ but in neurosurgery a platelet rate between 75 and $100,000/\text{mm}^3$ is required [17]. Our patient had a platelet count of $356,000/\text{mm}^3$.
3. Good preoperative management of anticoagulants. In our patient who had preventive LMWH anticoagulant treatment, the last dose was the day before, more than 24 hours earlier.
4. Correction of preoperative anemia. The detection of pre-operative anemia and its correction before a haemorrhagic intervention does not modify the haemorrhagic risk in itself but allows an increase in hemoglobinemia and a reduction in the need for transfusion [18]. Iron supplementation or the use of erythropoietin are the solutions to correct preoperative anemia. Our patient had no preoperative anemia.
5. Prevent intraoperative coagulopathy by preventing hypothermia, which is essential. Indeed, hypothermia decreases the generation of thrombin and the synthesis of fibrinogen by dysfunction of coagulation factors, leads to platelet dysfunction and endothelial dysfunction and increases fibrinolysis. Even a small

decrease in body temperature (less than 1 degree) increases blood loss by 16% and increases the relative risk of transfusion by 22% [19].

6. Intraoperatively, our patient's temperature was 37 degrees, maintained by a forced-air heater.
7. according to a meta-analysis, the administration of tranexamic acid reduced per and post-operative blood loss by 54% and the risk of transfusion by 40% in spinal surgery (20).
8. usually the loading dose is around 10 to 25 mg.kg^{-1} , followed by a maintenance dose between 1 and 4 mg/kg/h . Our patient received 1g of tranexamic acid at the beginning of the procedure and 500mg at the end of the procedure.

Postoperative pain is significant after major spine surgery and requires a multimodal analgesia strategy.

The nociceptive stimuli come from the skin incision, the thoraco-lumbar muscles, bone and joint lesions, ligament or joint lesions and intervertebral discs. In addition, neuropathic pain, due to compression or nerve root damage, precedes surgery in many patients. This perineural pain, often associated with chronic inflammation, is responsible for pain sensitization phenomena that can go as far as hyperalgesia or allodynia.

An initial titration with morphine followed by morphine in self-controlled analgesia has long been a reference method. However, some patients with chronic spinal pain receive morphine derivatives for a prolonged period before the operation, causing the acquisition of morphine tolerance [21] [22]. Morphine spinal anesthesia is another option, which provides analgesia for 24 hours [23].

Nonsteroidal anti-inflammatory drugs (NSAIDs) are very effective in spine surgery. They reduce pain and the consumption of post-operative morphine. Ketamine infusion has some popularity, based on studies with small numbers appearing to show postoperative and long-term pain reduction. However, these results are inconsistent in the literature [24].

Gabapentinoids (pregabalin, gabapentin) reduce morphine doses and improve pain scores, but they are effective especially at high doses, leading to vigilance disorders. These agents should probably be reserved for patients suffering from neuropathic pain that precedes surgery or for those under chronic treatment with high doses of opioids [25, 26].

Lidocaine has anti-inflammatory, analgesic and anti-hyperalgesic properties which justify its use in per- and postoperative intravenous infusion with some positive studies [27].

The administration of local anesthetics can also be done with the infiltration of the muscles with a long-acting anesthetic (naropaine or bupivacaine), allowing postoperative analgesia for a few hours.

There is therefore no single analgesia technique, but it is the combination of morphine, NSAIDs, paracetamol, muscle infiltration with a local anesthetic that provides effective analgesia.

Our patient benefited at the end of the intervention from an

intrathecal injection of 200 gamma of morphine and paracetamol 1g + 100mg of tramadol + ketoprofen 100mg.

Postoperatively, the analgesia protocol included:

Paracetamol 1g 4 times a day combined with tramadol+ levosulpiride with an electric syringe pump and profenid 100mg 3 times a day.

This allowed to have EVA lower than 3.

Postoperative complications depend on age, nutritional status (albuminemia ≤ 35 g/l) and duration of surgery (sup 120 min). The most common complications are suppuration, deep vein thrombosis and spinal epidural hematoma. Despite the prolonged duration of the intervention of 07 hours in our patient, the postoperative course was simple with discharge from intensive care after 48 hours and from the hospital on D10.

4. Conclusion

The royal tumor is a neurofibroma with a monstrous growth that can jeopardize the functional prognosis of the patient before the intervention.

The dorsal locations of the tumor pose several problems.

The anesthetic management must take into account the risks of planned difficult intubation, the intraoperative installation in ventral decubitus and the significant intraoperative hemorrhage.

Malignant degeneration is possible and often affects the prognosis.

Conflicts of Interest

All the authors do not have any possible conflicts of interest.

References

- [1] Acko-Ohui E, Gui-Bilé L, Acko U et al (2020) The royal tumor of neurofibromatosis type 1: A case of discovery in Côte d'Ivoire RAFMI; 7 (2): 55-60.
- [2] N Holl, L Kremer, R Wosfram- Gabel, J-L Dietmann (2010) Intracanal spinal spaces: from radiological anatomy to etiological diagnosis. J Radiol; 9: 950-68.
- [3] Quekel LG, Versteeg CW (1995) The "dural tail sign" in MRI of spinal meningiomas. J Comput Assist Tomogr; 19: 890-2 PMID: 8537521 DOI: 10.1097/00004728-199511000-00009.
- [4] Mc Carron K, Goldblum J. (1998) Plexiform neurofibroma with and without associated malignant peripheral nerve sheath tumor: a clinicopathologic and immunohistochemical analysis of 54 cases. Mod Pathol; 11 (7): 612-7 PMID: 9688181.
- [5] Tchernev G, Chokoeva A, Patterson JW, Bakardzhiev I, Wollina U, Tana C. (2016) Plexiform Neurofibroma: A Case Report. Médecine (Baltimore); 95 (6) DOI: 10.1097/MD.0000000000002663.
- [6] Roth RR, Martinez R, James WD. (1987) Neurofibromatosis segmental. Arch Dermatol; 123 (7): 917-20. PMID: 3111388.
- [7] L. RAVOLAMANANA RALISATA, L. NANY (2001) Place of surgery in the treatment of extensive cutaneous lesions of Von Recklinghausen's disease Black African medicine: 2001, 48 (2).
- [8] Boulay G, Hamza J. Anesthesia and a Full Stomach (2002) 44th National Congress of Anesthesia and Resuscitation. Doctors. Update conferences: SFAR 2002; 217-26. PMID: 15577733.
- [9] Cissé M, Konaté I, Ka O, Dieng M, Tendeng J, et al. (2009) Emergency laparoscopy at the Surgical Clinic of Aristide Le Dantec Hospital in Dakar: the first 100 cases. e- memoirs of the National Academy of Surgery 2009; 8: 78-81.
- [10] Youguang Gao, Bo Lin, Jinghao Huang, Xianzhong Lin* and Caizhu Lin. (2019) Flexible video endoscope versus Macintosh laryngoscope for orotracheal tracheal intubation in the lateral position: a study protocol for a randomized controlled trial. 20: 166 DOI: 10.1186/s13063-019-3263-1.
- [11] Branka Maldini, Iljaz Hodžović, Tatjana Goranović, Jasna Mesarić. (2016) CHALLENGES IN THE USE OF VIDEO LARYNGOSCOPES Mar;55 Suppl 1: 41-50. PMID: 27276771.
- [12] Ravi Bhat, Channabasavaraj S Sanickop, Manjunath C Patil, Vijay S Umrani, Mallikarjun G Dhorigol (2015) Comparison of Macintosh laryngoscope and C-MAC video laryngoscope for intubation in lateral position Apr-Jun 2015; 31 (2): 226-9. DOI: 10.4103/0970-9185.155221.
- [13] S Molliex, J Ripart (2011) Positions in anesthesia: recent data 53rd national congress of anesthesia and resuscitation Physicians. Update Conference © 2011 Sfar. All rights reserved.
- [14] Kla KM, Lee LA. (2016) Perioperative visual loss. Best practice & research Clinical anaesthesiology.; 30 (1): 69-77. PMID: 27036604 DOI: 10.1016/j.bpa.2015.11.004.
- [15] Schonauer C, Bocchetti A, Barbagallo G, Albanese V, Moraci A. (2004) Positioning on surgical table. European spine journal: official publication of the European Spine Society, the European Spinal Deformity Society, and the European Section of the Cervical Spine Research Society. 2004; 13 Suppl 1: S50-5. PMID: 15221573 DOI: 10.1007/s00586-004-0728-y.
- [16] Bruder Nicolas (2018) Anesthesia for Lumbar Spine Surgery. Update Conference 2018 Sfar. All rights reserved.
- [17] Marret E, Ohana M. (2006) Management of thrombocytopenia in anesthesia. Update conferences SFAR: 95–112.
- [18] Lin DM, Lin ES, Tran M-H. (2013) Efficacy and safety of erythropoietin and intravenous iron in perioperative blood management: a systematic review. Transfus Med Rev 2013; 27: 221–34. PMID: 24135037 DOI: 10.1016/j.tmr.2013.09.001.
- [19] Rajagopalan S, Mascha E, Na J, Sessler DI. (2008) The effects of mild perioperative hypothermia on blood loss and transfusion requirement. Anesthesiology 10 2008; 108: 71–7. PMID: 18156884 DOI: 10.1097/01.anes.0000296719.73450.52.
- [20] Henry DA, Carless PA, Moxey AJ, O'Connell D, Stokes BJ, Fergusson DA, et al. (2011) Anti-fibrinolytic use for minimising perioperative allogeneic blood transfusion. Cochrane Database Syst Rev 2011: CD001886. PMID: 21412876 DOI: 10.1002/14651858.CD001886.pub4.

- [21] Franklin GM, Rahman EA, Turner JA, Daniell WE, Fulton-Kehoe D. (2009) Opioid use for chronic low back pain: A prospective, population-based study among injured workers in Washington state, 2002-2005. *The Clinical journal of pain.* 2009; 25 (9): 743-51. PMID: 19851153 DOI: 10.1097/AJP.0b013e3181b01710.
- [22] Webster BS, Verma SK, Gatchel RJ. (2007) Relationship between early opioid prescribing for acute occupational low back pain and disability duration, medical costs, subsequent surgery and late opioid use. *Spine.* 2007; 32 (19): 2127-32. PMID: 17762815 DOI: 10.1097/BRS.0b013e318145a731.
- [23] Gall O, Aubineau JV, Berniere J, Desjeux L, Murat I. (2001) Analgesic effect of low- dose intrathecal morphine after spinal fusion in children. *Anesthesiology.* 2001; 94 (3): 447-52. PMID: 11374604 DOI: 10.1097/00000542-200103000-00014.
- [24] Dunn LK, Durieux ME, Nemergut EC. (2016) Non-opioid analgesics: Novel approaches to perioperative analgesia for major spine surgery. *Best practice & research Clinical anaesthesiology.* 2016; 30 (1): 79-89. PMID: 27036605 DOI: 10.1016/j.bpa.2015.11.002.
- [25] Peng C, Li C, Qu J, Wu D. (2017) Gabapentin can decrease acute pain and morphine consumption in spinal surgery patients: A meta-analysis of randomized controlled trials. *Medicine.* 2017; 96 (15): e6463. PMID: 28403075 DOI: 10.1097/MD.00000000000006463.
- [26] Jiang HL, Huang S, Song J, Wang X, Cao ZS. (2017) Preoperative use of pregabalin for acute pain in spine surgery: A meta-analysis of randomized controlled trials. *Medicine.* 2017; 96 (11): e6129. PMID: 28296725 DOI: 10.1097/MD.00000000000006129.
- [27] Farag E, Ghobrial M, Sessler DI, Dalton JE, Liu J, Lee JH, et al. (2013) Effect of perioperative intravenous lidocaine administration on pain, opioid consumption, and quality of life after complex spine surgery. *Anesthesiology.* 2013; 119 (4): 932-40. PMID: 23681143 DOI: 10.1097/ALN.0b013e318297d4a5.