

# A Patient with Extremely Severe Constrictive Pericarditis Underwent Emergency Pericardiectomy Without Cardiopulmonary Bypass

Danfeng Xu, Xuejie Li\*

Department of Anesthesiology, West China Hospital, Sichuan University and the Research Units of West China (2018RU012), Chinese Academy of Medical Sciences, Chengdu, China

## Email address:

xudanfeng@wchscu.cn (Danfeng Xu), lizuima@hotmail.com (Xuejie Li)

\*Corresponding author

## To cite this article:

Danfeng Xu, Xuejie Li. A Patient with Extremely Severe Constrictive Pericarditis Underwent Emergency Pericardiectomy Without Cardiopulmonary Bypass. *International Journal of Anesthesia and Clinical Medicine*. Vol. 11, No. 1, 2023, pp. 32-34.

doi: 10.11648/j.ijacm.20231101.17

Received: March 23, 2023; Accepted: April 10, 2023; Published: April 15, 2023

**Abstract:** We report a case of a 58-year-old man admitted to hospital with severe constrictive pericarditis. An emergency pericardiectomy was planned due to the patient's orthopnea associated with hemodynamic instability. The patient performed pericardiectomy without cardiopulmonary bypass. The patient was found to be orthopnea and began to experience disturbance of consciousness after entering the operating room. Non-invasive blood pressure was 100/54 mmHg, accompanied by atrial fibrillation, the ventricular rate was 158 beats/min, and arterial oxygen saturation was 90% with air inhalation. After intubation, the ventricular rate rose to 187 beats/min, the blood pressure dropped to 65/45 mmHg, and vasopressors were urgently administered to maintain circulatory stability. At the same time, the internal jugular vein cannula was placed ultrasound-guided. During the operation, the central venous pressure (CVP) increased to 41.2 cmH<sub>2</sub>O, and cerebral oxygen saturation dropped to 47.6%. Although the patient with severe constrictive pericarditis, we still performed pericardiectomy without cardiopulmonary bypass. The operation time was about 3 hours, and the patient was successfully transferred to the Intensive Care Unit (ICU) to continue monitoring and treatment, and the tracheal intubation was removed 48 hours after the operation and he was discharged 19 days after the operation. Real-time transesophageal echocardiography (TEE) monitoring played a crucial role in intraoperative management.

**Keywords:** Constrictive Pericarditis, Disturbance of Consciousness, Pericardiectomy, Transesophageal Echocardiography

## 1. Introduction

Constrictive pericarditis (CP) is an inflammatory disease of the lobules of the pericardium, resulting in thickening and fibrosis of the pericardium [1-3]. These irreversible pericardial changes eventually lead to impairment of diastolic filling and right heart failure [1-3]. The etiology of pericardial disease mainly includes infectious and non-infectious diseases. It is currently the cause of constrictive pericarditis, including tuberculosis, infection, radiotherapy, cardiac surgery, trauma, etc. The most common cause of pericarditis in developing countries is tuberculosis [4]. Tuberculosis is the prevalent etiology in China, but the proportion is decreasing [5].

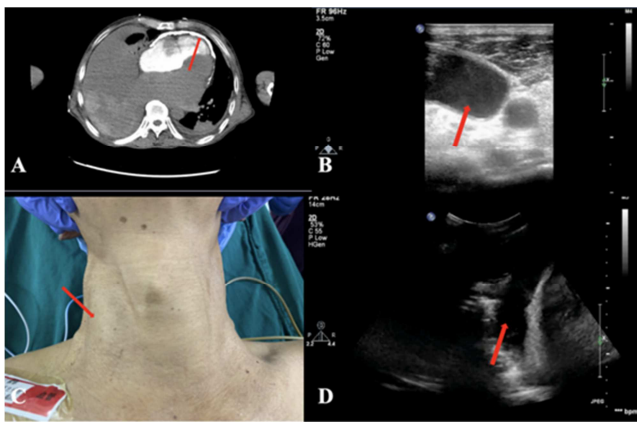
Surgical treatment of CP is required for all patients with dyspnea and worsening of weakness, special symptoms of right ventricular diastolic dysfunction, such as jugular vein swelling, leg and foot edema, hepatomegaly, ascites, palpitation, oliguria, and low cardiac output [6, 7]. Complete pericardiectomy is the ideal treatment option to remove the contraction. Herein, we describe a patient with extremely severe constrictive pericarditis undergoing emergency pericardiectomy.

## 2. Case Presentation

A 58-year-old man developed heart tiredness, chest tightness, and shortness of breath after exercising half a year

ago. He needed to sleep on a pillow to keep his head up at night and was accompanied by symptoms of epigastric fullness, loss of appetite, and fatigue. At the local hospital, the diagnosis was constrictive pericarditis. He was admitted to the emergency department due to dyspnea and orthopnea. He was diagnosed with constrictive pericarditis with moderate mitral and tricuspid regurgitation by transthoracic echocardiography (TTE), and Computed Tomography (CT) showed thickening of the pericardium (Figure 1A). An emergency pericardiectomy was planned due to the patient's orthopnea associated with hemodynamic instability.

After entering the operating room, he was found to be sweating profusely and began to experience disturbance of consciousness. Non-invasive blood pressure was 100/54 mmHg, accompanied by atrial fibrillation, the ventricular rate was 158 beats/min, and arterial oxygen saturation was 90% with air inhalation. The patient's right internal jugular vein was markedly enlarged (Figure 1B), with strong spontaneous imaging but no thrombosis, and the common carotid artery was very small (Figure 1C). Bedside ultrasonography revealed a massive right-sided pleural effusion with atelectasis (Figure 1D). After intubation, the ventricular rate rose to 187 beats/min, the blood pressure dropped to 65/45 mmHg, and vasopressors were urgently administered to maintain circulatory stability. At the same time, the internal jugular vein cannula was placed ultrasound-guided. Cardiopulmonary bypass was on standby.

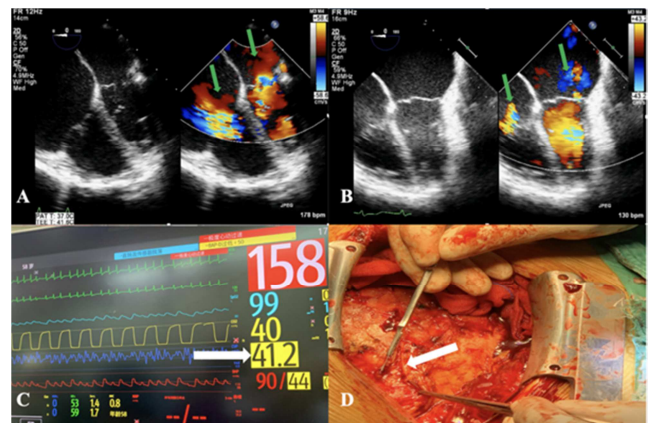


**Figure 1.** A CT showed thickening of the pericardium (red arrow). B Right internal jugular vein was markedly enlarged, with strong spontaneous imaging (red arrow). C The patient's internal jugular vein was markedly enlarged (red arrow). D Bedside ultrasonography revealed a massive right-sided pleural effusion with atelectasis (red arrow).

TEE probe was placed after intubation, and the mid-esophagus 4-chamber view showed: that the patient's pericardium was thickened, the double atrium was enlarged, and the double ventricle was reduced; with moderate mitral regurgitation and moderate tricuspid regurgitation, left and right ventricular systolic function was normal (Figure 2A). Vasoactive drugs were used under the guidance of TEE to limit fluid infusion. Median sternotomy was performed (Figure 2D). The pericardium showed generalized thickening with calcification at the anterior and inferior parts. During the operation, the CVP increased to 41.2 cmH<sub>2</sub>O (Figure 2C),

while the mean artery pressure (MAP) was 59 mmHg at this time.

The operation was performed smoothly, and the patient's circulation became stable after the pericardial restriction was relieved. Immediate postoperative TEE showed mild mitral regurgitation, mild tricuspid regurgitation, and normal left and right ventricular systolic function (Figure 2B). The operation time was about 3 hours, and the patient was successfully transferred to the Intensive Care Unit (ICU) to continue monitoring and treatment, and the tracheal intubation was removed 48 hours after the operation. Hypoalbuminemia was actively treated and organ perfusion was corrected after the operation. After meticulous management, the patient was discharged 19 days after the operation. The patient had a small amount of pleural effusion and ascites, and the edema of both lower extremities disappeared. Echocardiography showed mild mitral regurgitation and mild tricuspid regurgitation 30 days after discharge.



**Figure 2.** A The patient's pericardium was thickened, the double atrium was enlarged, and the double ventricle was reduced; moderate mitral regurgitation, moderate tricuspid regurgitation (green arrow). B Postoperative TEE showed mild mitral regurgitation, mild tricuspid regurgitation (green arrow), and normal left and right ventricular systolic function. C CVP increased to 41.2 cmH<sub>2</sub>O during the operation (white arrow). D The pericardium was found to be thickened and hardened during the operation.

### 3. Discussion

The description of constrictive pericarditis dates back to more than 400 years and is attributed primarily to Richard Lower, who recognized the typical features of the disease in 1669 [8]. The first attempt to relieve the restricted heart was based on Brauer's cardiolysis surgery, in which some of the costal cartilage and part of the sternum near the left heart were removed [9]. Surgical treatment of CP is required for all patients with dyspnea and worsening of weakness, special symptoms of right ventricular diastolic dysfunction, such as jugular vein swelling, leg and foot edema, hepatomegaly, ascites, palpitation, oliguria, and low cardiac output [6, 7]. Complete pericardiectomy is the ideal treatment option to remove the contraction. The patient we encountered was a very severe patient with typical jugular venous distention, and lower extremity edema, combined with hypoalbuminemia,

pleural effusion, ascites anuria, and low cardiac output.

Although there have been significant improvements over the years, as a report confirms at Mayo Clinic by Murashita et al [10], where the 30-day mortality decreased significantly from 13.5% (35 of 259 patients), in the historical era (pre-1990), to 5.2% (42 of 807) in the contemporary era, and recently reported in the literature the perioperative mortality rates after pericardiectomy for CP in western countries was 2.1% (1 of 47) to 18.6% (18 of 97) [11]. Therefore, patients with such severe constrictive pericarditis have a very high risk of surgery and a high mortality rate. This is the first time that our center has encountered such a critical situation that CP causes disturbance of consciousness. Use of cardiopulmonary bypass (CPB) was found to be an independent predictor of patients' complex hospitalization duration [12]. Patients do not need to use an extracorporeal circulation machine during surgery, because clinical trials have shown that the use of extracorporeal circulation within 30 days of surgery has a higher mortality rate than without cardiopulmonary bypass [13, 14]. In our study, CPB use was the only predictor of in-hospital mortality, and these results are consistent with those found in other studies [15]. Although our patient's condition is very critical, in order to ensure a good prognosis, it is planned not to use the cardiopulmonary bypass, which undoubtedly increases the difficulty of anesthesia management. Another dilemma is valvular regurgitation, especially tricuspid regurgitation. We do not advocate concurrent tricuspid valve surgery in patients with constrictive pericarditis. Patients undergoing pericardiectomy have a considerable probability of postoperative vascular paralysis. The combination of these two procedures can even exacerbate the long-term need for vasoconstrictors, leading to prolonged ICU stays, in addition to necessitating cardiopulmonary bypass. In this case, the patient still chose not to deal with tricuspid regurgitation. In addition to the influence factors of cardiopulmonary bypass, it was also considered that the right ventricular pressure could be reduced after the pericardial restriction was relieved, thereby reducing tricuspid regurgitation. Intraoperative real-time TEE monitoring also confirmed our speculation that the patient's postoperative tricuspid regurgitation was mild.

Hypalbuminemia was actively treated in the intensive care unit postoperative and vasopressors were used to maintain circulatory stability. The patient was discharged after 19 days. Echocardiography showed mild mitral regurgitation and mild tricuspid regurgitation after discharge. Left and right ventricular systolic function were normal. The patient had a small amount of pleural effusion and ascites, and the edema of both lower extremities disappeared.

## 4. Conclusion

In conclusion, although this is an emergency patient with constrictive pericarditis accompanied by disturbance of consciousness, we still performed pericardiectomy without cardiopulmonary bypass. Real-time monitoring of TEE is very important for intraoperative management.

## Conflict of Interests

All the authors do not have any possible conflicts of interest.

## References

- [1] Welch T D, Oh J K. Constrictive pericarditis [J]. *Cardiology clinics*, 2017, 35 (4): 539-549.
- [2] Welch T D. Constrictive pericarditis: diagnosis, management and clinical outcomes [J]. *Heart*, 2018, 104 (9): 725-731.
- [3] Di Lazzaro D, Di Bella I, Pasquino S, Berti V, Da Col U. Pericardiectomy for constrictive pericarditis. *Multimed Man Cardiothorac Surg*. 2020 Dec 22; 2020.
- [4] Chang S A, Oh J K. Constrictive Pericarditis: A Medical or Surgical Disease? [J]. *Journal of cardiovascular imaging*, 2019, 27 (3): 178-186. DOI: 10.4250/jcvi.2019.27.e28.
- [5] Zhu P, Mai M, Wu R, et al. Pericardiectomy for constrictive pericarditis: single-center experience in China [J]. *Journal of cardiothoracic surgery*, 2015, 10: 1-5.
- [6] Sultan F A T, Tariq M U. Clinical features, management and outcome of patients with constrictive pericarditis—Experience from a third world country [J]. *Journal of the Saudi Heart Association*, 2018, 30 (1): 9-13.
- [7] Schwefer M, Aschenbach R, Heidemann J, et al. Constrictive pericarditis, still a diagnostic challenge: comprehensive review of clinical management [J]. *European journal of cardio-thoracic surgery*, 2009, 36 (3): 502-510.
- [8] Sellors T H. Constrictive pericarditis [J]. *Journal of British Surgery*, 1946, 33 (131): 215-230.
- [9] Brauer L. Die Kardiolyse und ihre indikationen [J]. *Arch Klin Chir*, 1903, 71: 258.
- [10] Murashita T, Schaff H V, Daly R C, et al. Experience with pericardiectomy for constrictive pericarditis over eight decades [J]. *The Annals of thoracic surgery*, 2017, 104 (3): 742-750.
- [11] Busch C, Penov K, Amorim P A, et al. Risk factors for mortality after pericardiectomy for chronic constrictive pericarditis in a large single-centre cohort [J]. *European Journal of Cardio-Thoracic Surgery*, 2015, 48 (6): e110-e116.
- [12] Gatti G, Fiore A, Ternacle J, et al. Pericardiectomy for constrictive pericarditis: a risk factor analysis for early and late failure [J]. *Heart and Vessels*, 2020, 35: 92-103.
- [13] Rupprecht L, Putz C, Flörchinger B, et al. Pericardiectomy for constrictive pericarditis: an institution's 21 years experience [J]. *The Thoracic and cardiovascular surgeon*, 2018, 66 (08): 645-650.
- [14] Karima T, Nesrine BZ, Hatem L, Skander BO, Raouf D, Selim C. Constrictive pericarditis: 21 years' experience and review of literature. *Pan Afr Med J*. 2021 Feb 8; 38: 141.
- [15] Tokuda Y, Miyata H, Motomura N, et al. Outcome of pericardiectomy for constrictive pericarditis in Japan: a nationwide outcome study [J]. *The Annals of thoracic surgery*, 2013, 96 (2): 571-576.